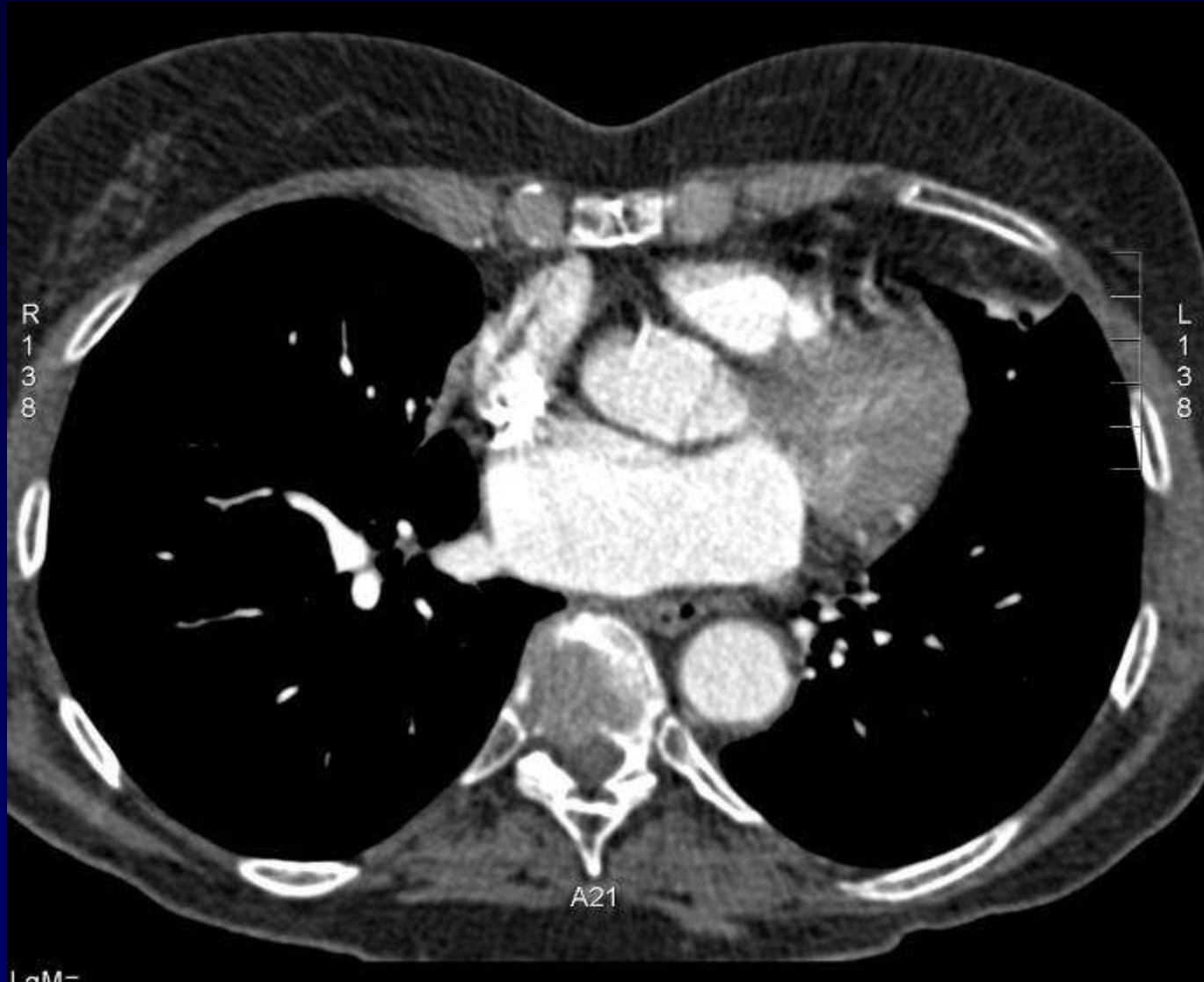


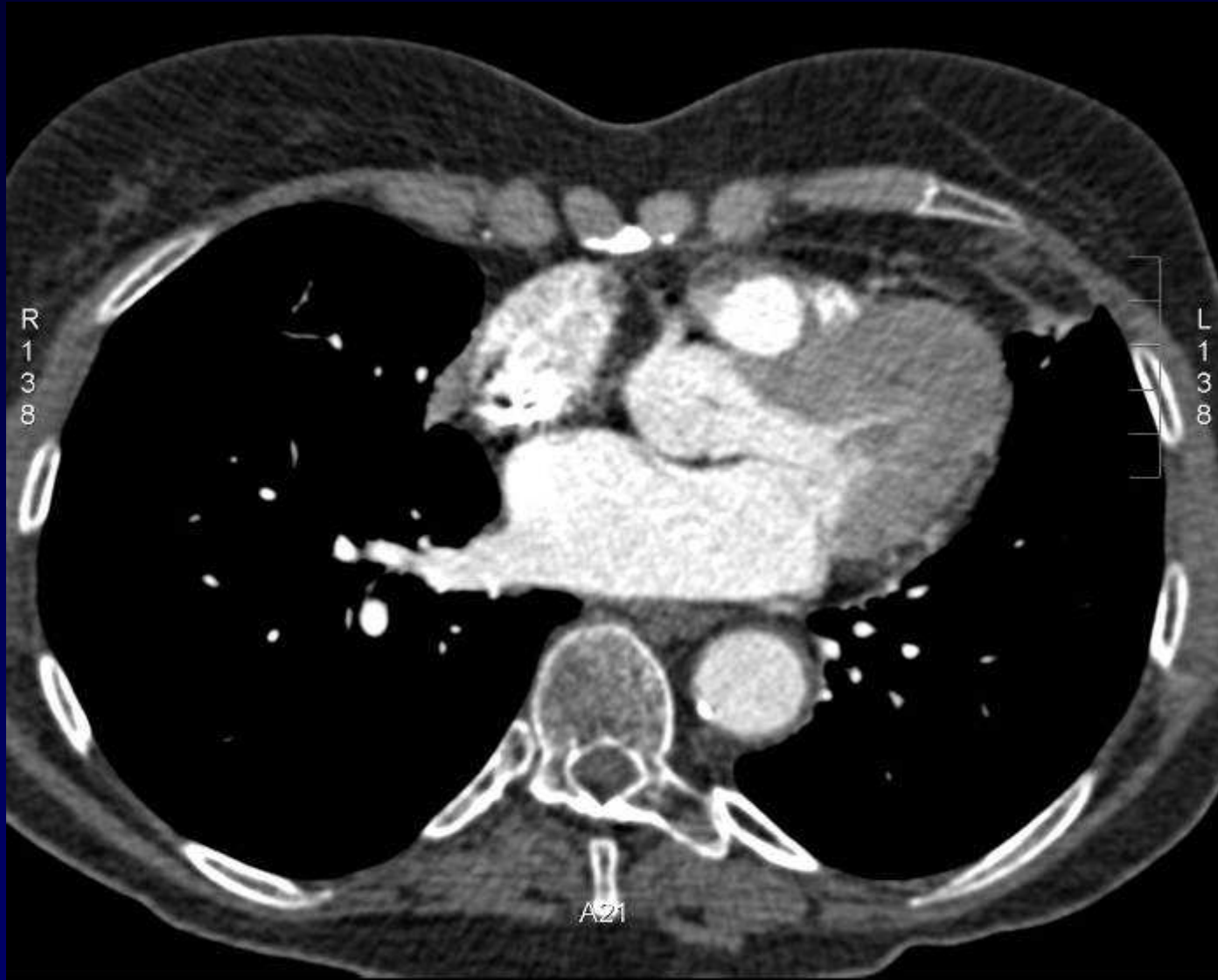

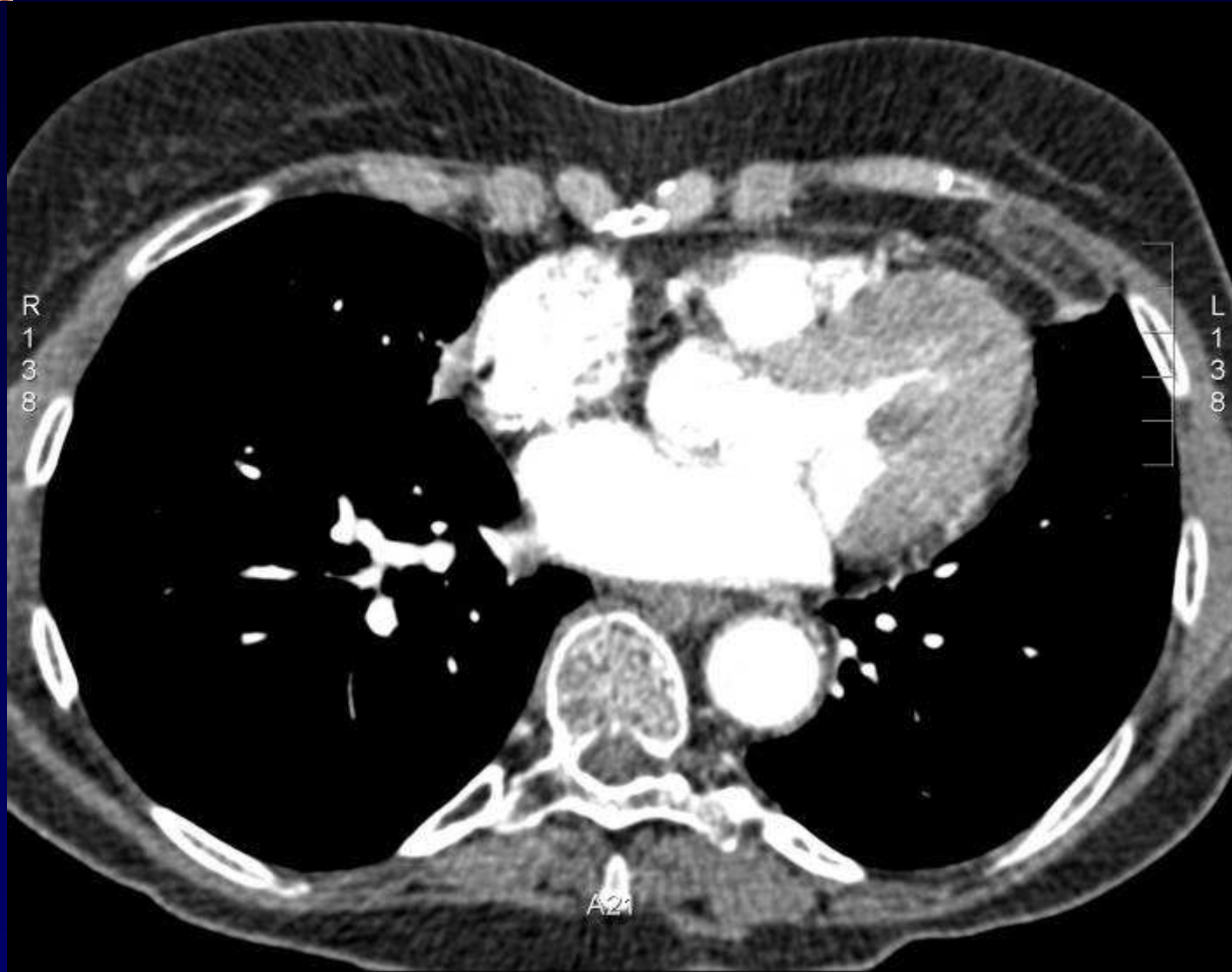Dossier 12

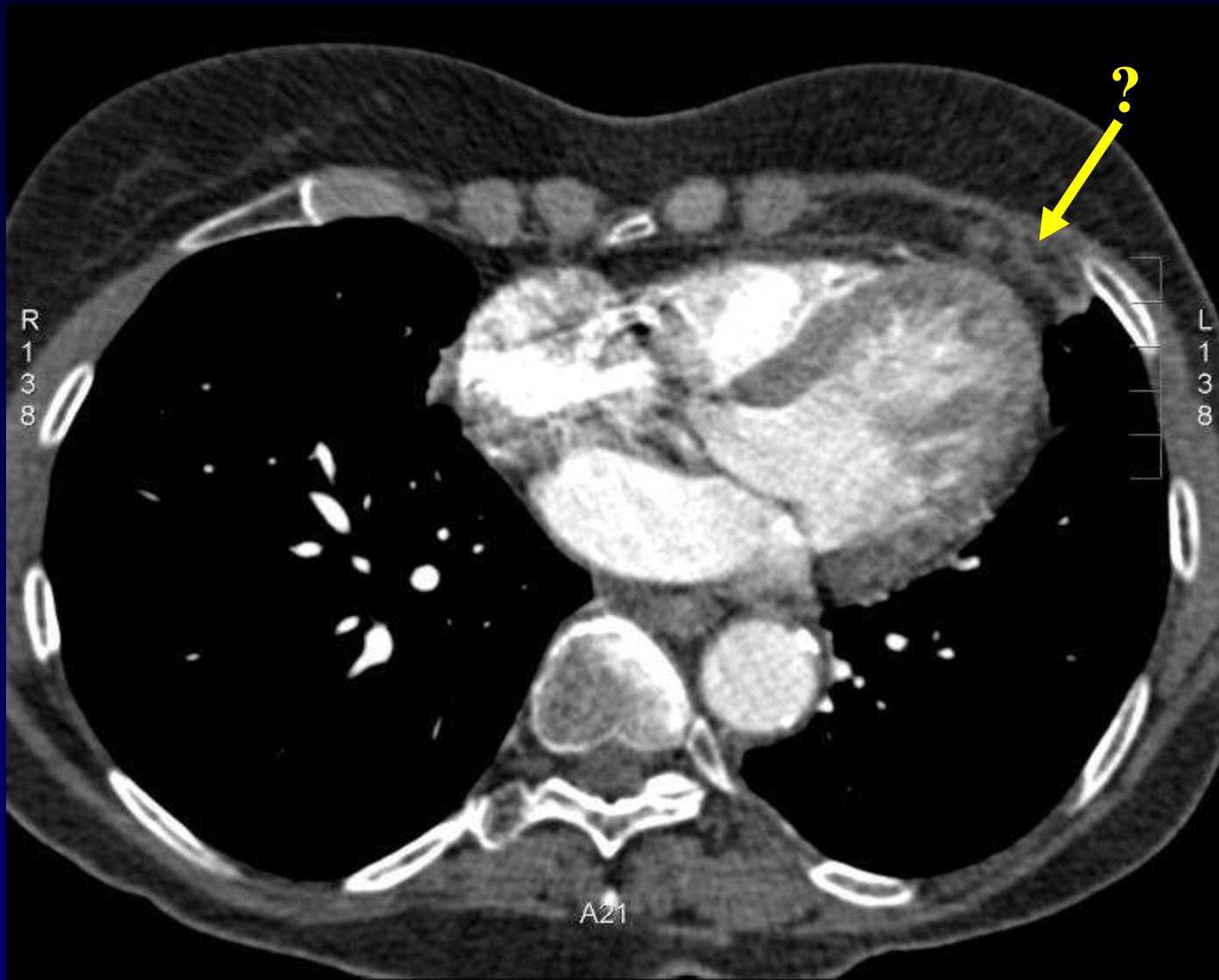
B. GHAYE

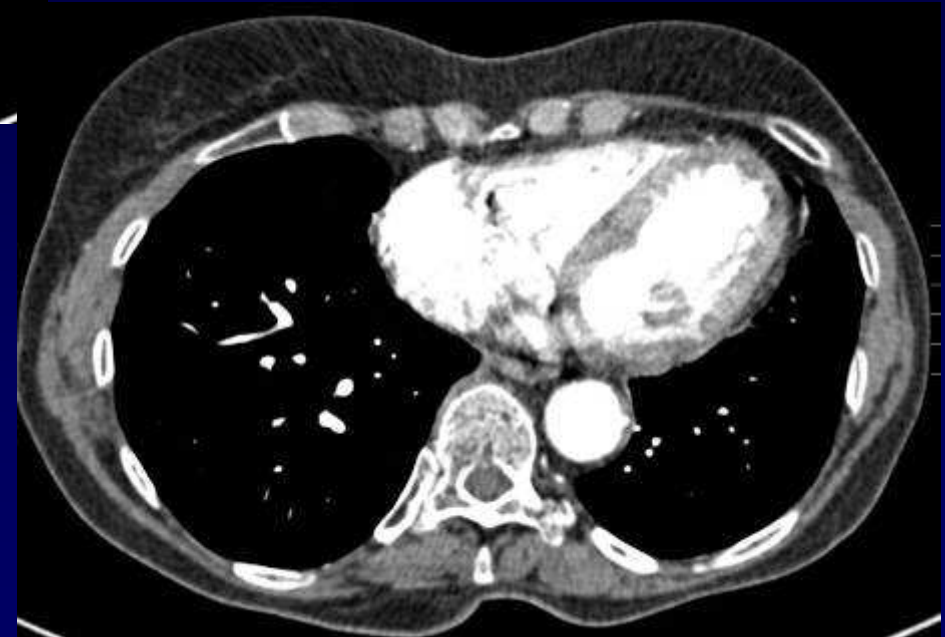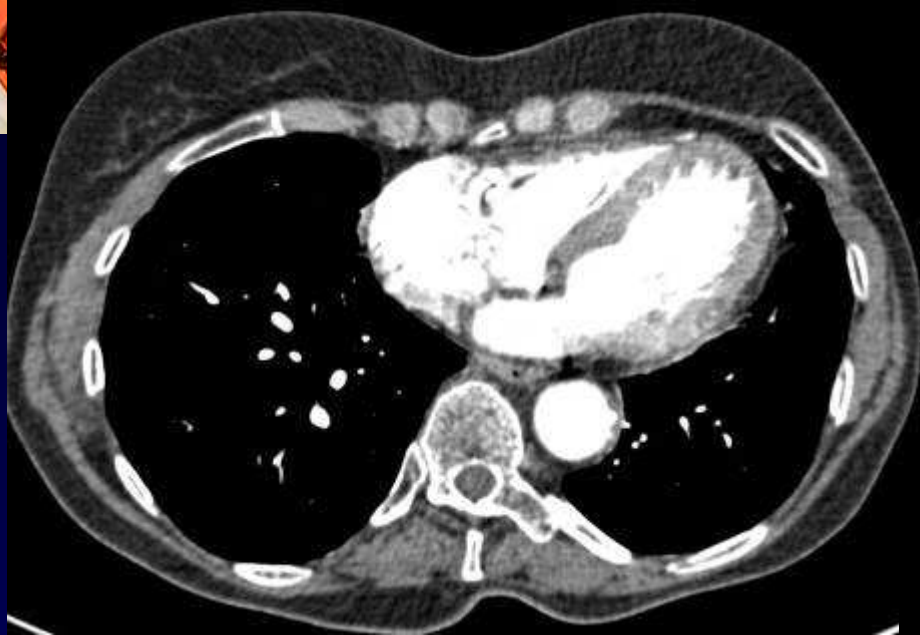
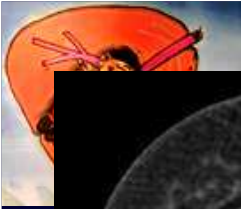
- **Femme de 73 ans**
- **Douleurs thoraciques gauches**











Scanner normal il y a un an

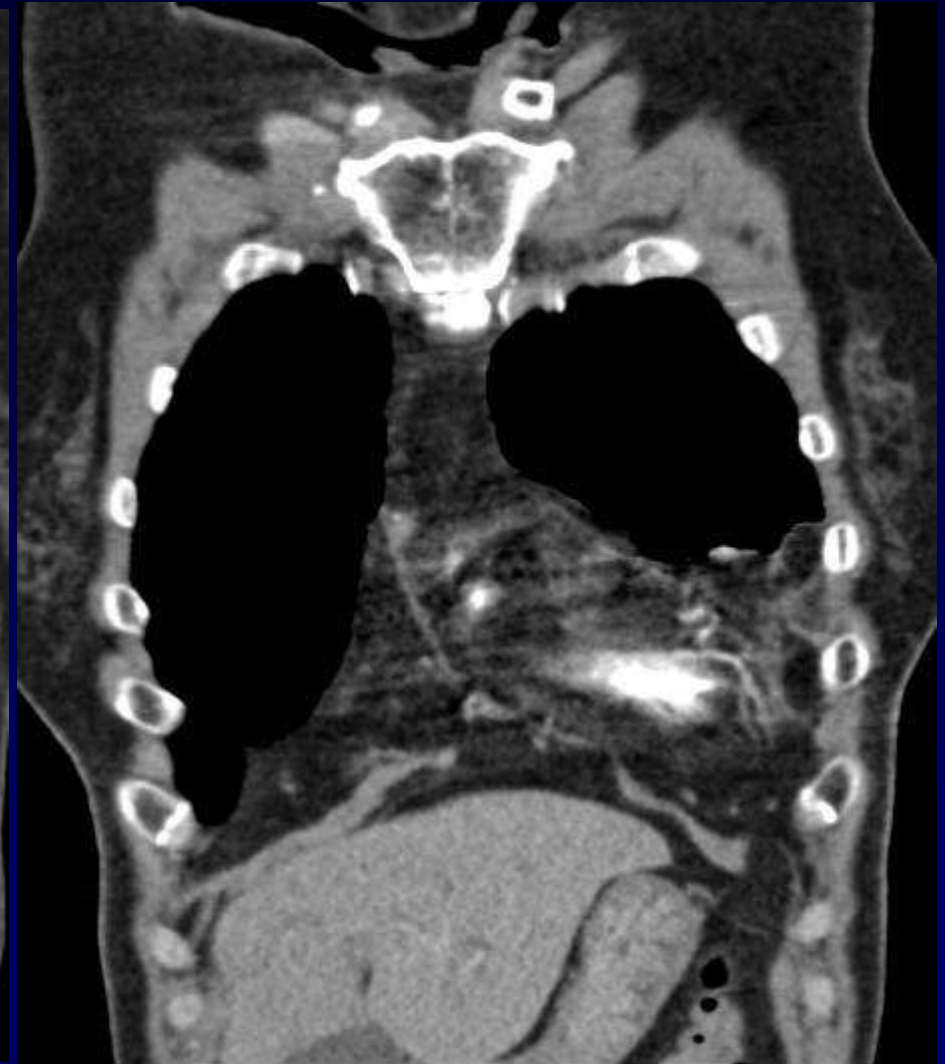
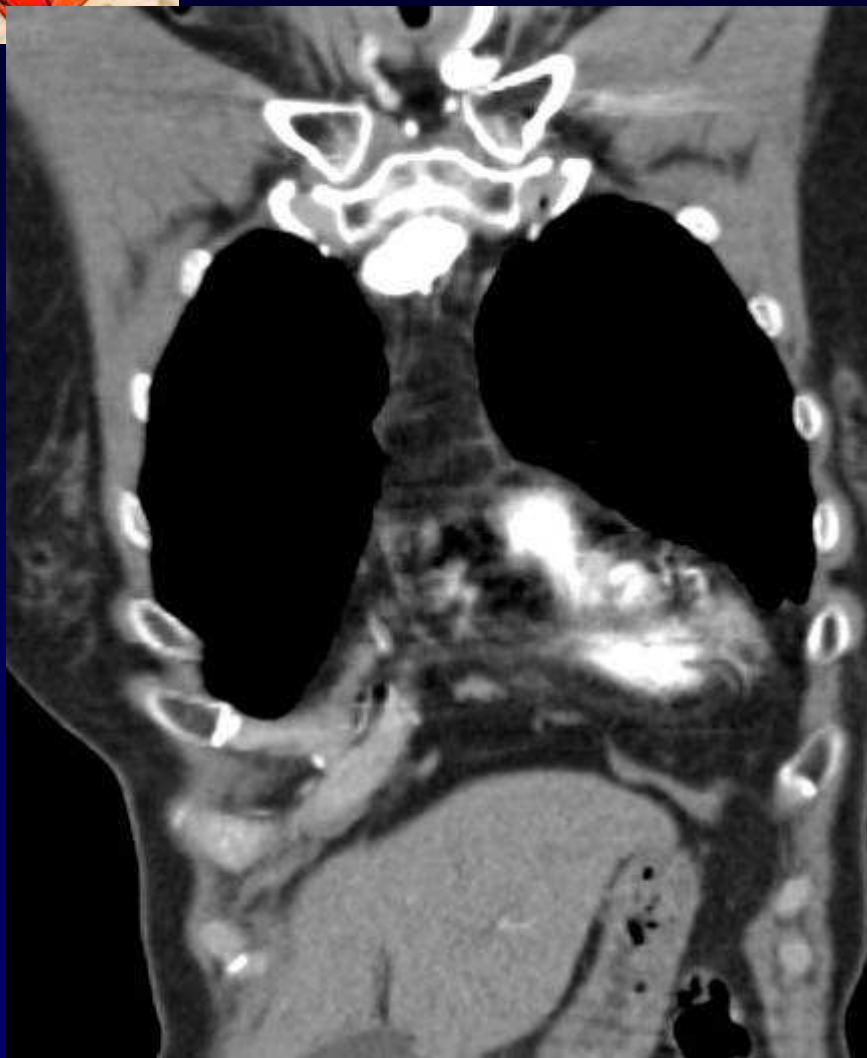
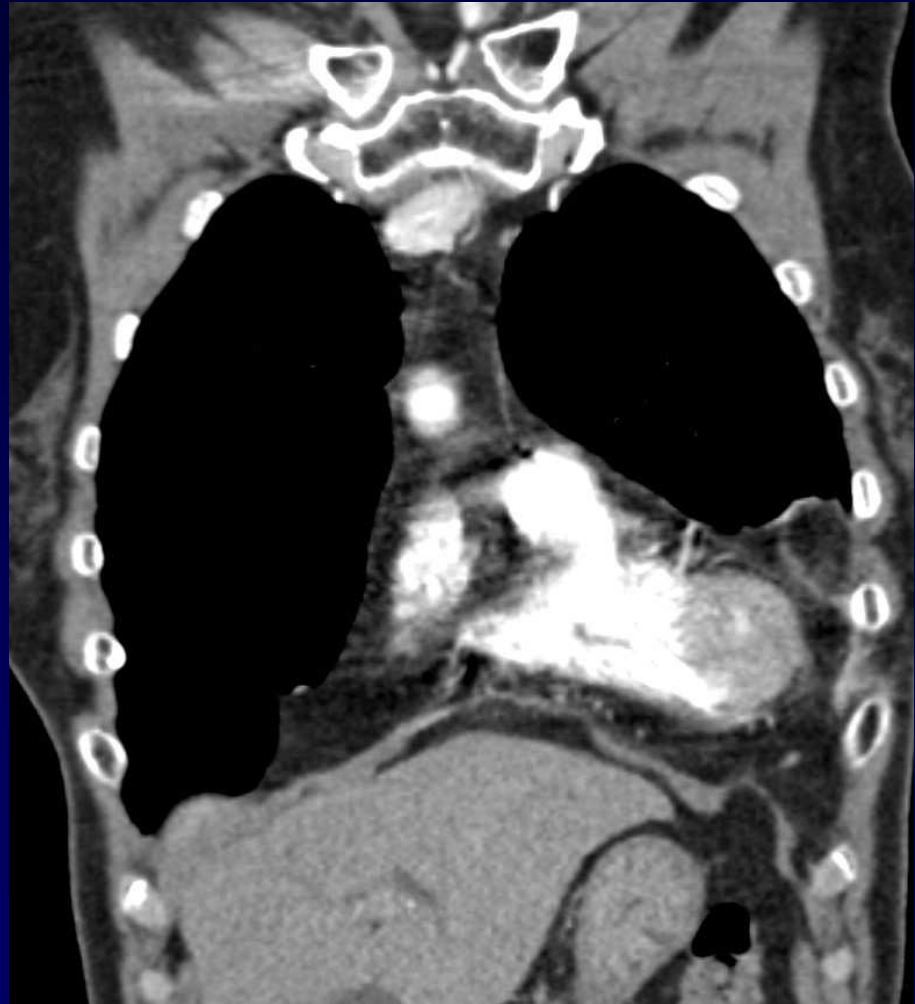
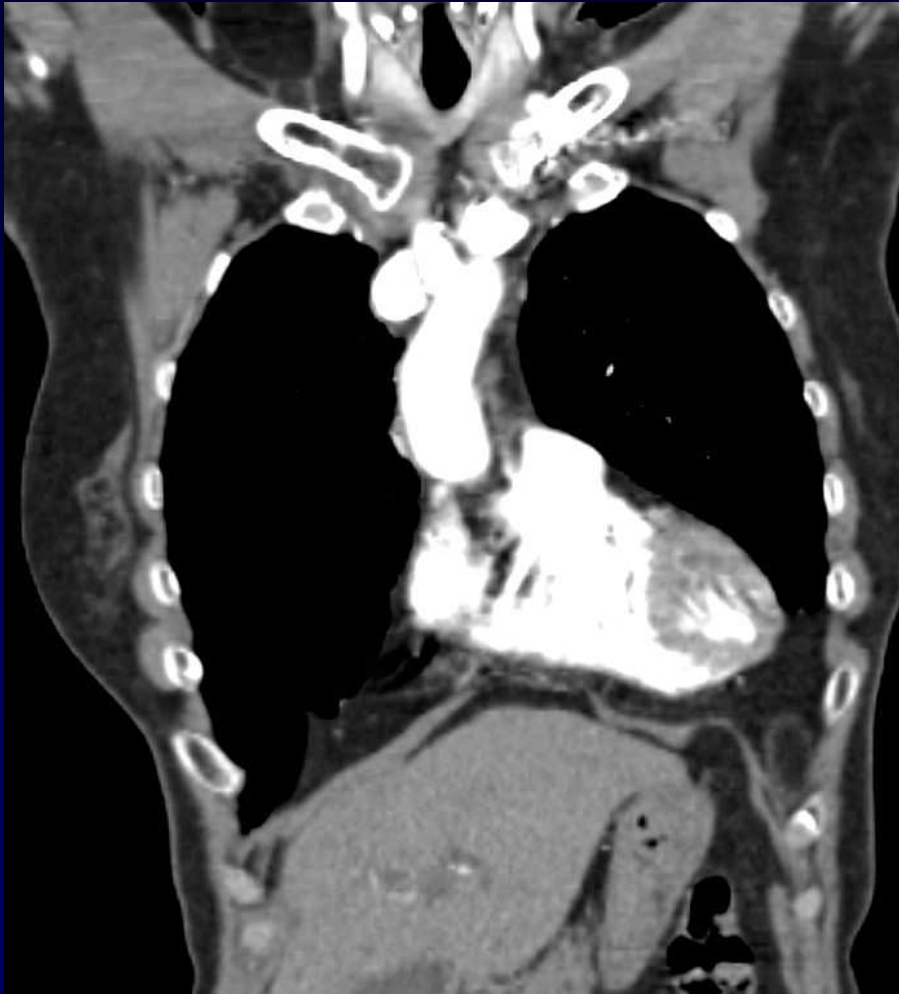Diagnostic ?



Appendagite

Codage: Paroi – Médiastin - Inflammatoire







Référence

Voir **Maladie de Dercum**